



Which Restorative?

A guide to the selection and use of glass ionomer restoratives from GC.

GC

Guide to the selection and use of glass ionomer technology **from GC.**

Restorative materials on today's market have evolved over time offering differences in performance, cost, ease of use, aesthetic appeal, long-term effectiveness and safety. This means that different clinical situations call for different materials.

Which restorative you select is important

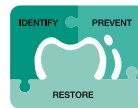In today's Minimum Intervention Treatment Plan concept, created by GC, managing patient's mouth's and oral cavities over time is key. Dentistry has evolved from a purely mechanical discipline to one that takes a more medical approach.

With this in mind, the type of restorative you choose for a particular indication is paramount as it can influence both the long-term outcome of the clinical procedure and how satisfied your patient is. Your choice can also impact your practice profitability, particularly if you routinely use one material. This is where differences in restoratives – ease of and time to use or accessories such as bonding agents – really come to the fore. And in some cases, you might need to combine materials to obtain the best result.

Staying practical is key: first decide which restorative or combination is best for the indication.

In general, it's a good idea to fully grasp each material's characteristics before you choose your restorative. Next, match these to how the material will have to perform in specific clinical situations.

Things to carefully consider: where will the restoration be – posterior or anterior? Where is the cavity and how big is it? What is the patient's risk of caries? How does it integrate into the Minimum Intervention Treatment Plan?



Minimum Intervention

However, suitability for the indication isn't your only concern – you need to take the material's other characteristics into account. Take the 'safe to use' aspect. If you know your patient is extremely sensitive to certain monomers, consider non-resinous materials.

Choosing a material which nicely balances performance and the cost and ease of use, may also prove critical, particularly if you frequently perform restorations and you need to keep an eye on patient turnover per hour. In these situations, choosing an easy-to-use restorative that works in a moist environment might be your best option.

GC GLASS IONOMER RESTORATIVES: essential in every dental practice.

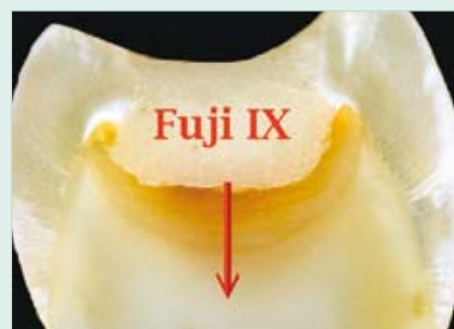
The most successful adherent system – clinically proven!

A recent systematic review of adhesive clinical trials ranked glass ionomer cement Number 1 in superior retention and clinical performance over resin adhesive systems (in other words, superior to etch and self etch, 3-step, 2-step and 1-step adhesives)*.

* Peumans M, Kanumilli P, De Munck J, Van Landuyt K, Lambrechts P, Van Meerbeek B. Clinical effectiveness of contemporary adhesives: A systemic review of current clinical trials. Dent Mater 2005;21:864-881.

Glass ionomers are so effective as an adhesive interface because they:

- are water-based cements with a unique matrix structure – perfect for the oral environment
- tolerate moisture during placement*
- chemically bond to dentine, enamel and cementum to create a strong, stable and chemically-fused seal
- withstand pulpal fluid flow (unlike resin adhesive systems)
- protect the surrounding tooth structure by releasing fluoride and strontium ions
- help stimulate internal remineralisation which releases strontium and fluoride ions, ultimately boosting the hardening process**
- eliminate bacteria in early stages
- achieve a positive pulpal response thanks to good biocompatibility
- have a coefficient of thermal expansion similar to dentine



* they require protection from moisture contamination straight after placement until the initial set has been reached.

** Remineralisation of carious dentine exposed to a glass ionomer, an in-vivo study. Ngo H, Mount GJ, Morris M McIntyre, Tuisuva J, Von Doussa R. J Dent Res 80 (IADR Abstract no 919) 2001."

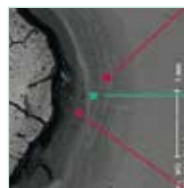
The fundamentals of glass ionomer technology

To achieve optimum clinical results, a clean, caries-free periphery around the dentin-enamel junction will allow the glass ionomer to help remineralise the underlying dentine. For teeth with deep lesions and a symptomless pulp, leave softened dentine on the cavity floor rather than risk pulpal exposure. GC glass ionomers use strontium containing glass, which are reported to be more effective at remineralising soft dentine.

Condition the cavity to remove any surface debris left after you've prepared the cavity. This also improves surface energy, so the glass ionomer will flow more smoothly and adapt to the cavity floor and walls for optimum chemical adhesion. What's more, conditioning minimises the risk of air entrapment and voids. The polyacrylic acid in Cavity Conditioner also prepares dentine and enamel for chemical adhesion without opening the dentine tubules, which rules out post-operative sensitivity. After washing off the conditioner, gently dry to remove excess moisture without desiccating the tooth.

The formation of a strong, chemically-fused seal: the most significant benefit you'll reap in using glass ionomer as the adhesive interface with the tooth.


In this SEM image, the acid-resistant chemically-fused seal appears as a raised ridge between Fuji IX GP and dentine. The specimen was taken from a tooth which had been restored with Fuji IX GP and subsequently extracted for unrelated reasons nine months later. The specimen was polished and etched for ten seconds to remove the smear layer. Then a resin impression was taken for SEM evaluation.



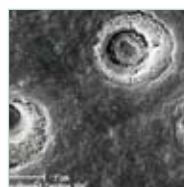
Remineralisation

Hypermineralisation

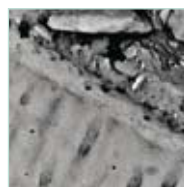
Remineralisation



Dentine surface with smear layer intact



Dentine surface after treatment with polyacrylic acid conditioner



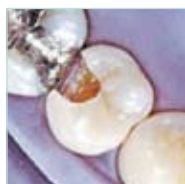Dr. H. Ngo



Proof that glass ionomer restorations greatly exceed expectations

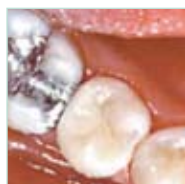In 1995, this patient required replacement of a Class II composite restoration. After checking the occlusion and load-bearing factors, the operator decided to apply the world's **first** high-strength glass ionomer material for pos-

terior use: Fuji IX. Why? This new glass ionomer provided a long-lasting seal, enduring protection and sufficient aesthetic appeal – all in one. **The results speak for themselves ...**



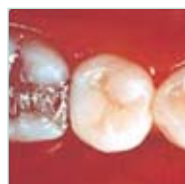1995

Prepared cavity after conditioning



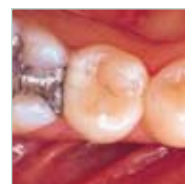1995

Final result after finishing and polishing



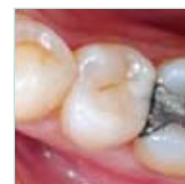1998

The same restoration three years later



2001

The same restoration six years later



2007

The same restoration twelve years later

Dr. J. Neo

GC Fuji IX: used in more than 250 million restorations worldwide

GC'S ONGOING COMMITMENT to glass ionomer research and innovation has driven recent developments: based on its proven glass ionomer technology.

Lamination strengthening - achieving optimum maturation.

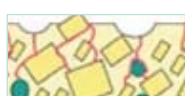G-Coat PLUS is a tough, nanofilled, self-adhesive coating that chemically bonds to Fuji IX GP and surrounding tooth surfaces. When applied to glass ionomer cements, this means that G-Coat PLUS hardens the lamination, markedly increasing the fracture restoration toughness as well as resistance to early wear and acid.

Glass ionomer restoration gather strength in two ways: internally and externally. Internally, the chemical reactions mature and strengthen the cement, and externally, the

uptake of calcium and phosphate from saliva strengthens the cement's surface. Based on our R&D findings, you'll achieve the greatest improvement by coating glass ionomer restoration with a protective layer. This allows the core of the restoration to mature and then over time allow delayed exposure to saliva to start the surface hardening process through uptake of calcium and phosphate. If this is what you need to do, you'll find no better coating material than G-Coat PLUS.



Glass ionomer surface



Mechanical stress concentrates on surface voids leading to crack propagation



G-Coat PLUS bonds to the surface and fills voids



Mechanical stress is dispersed by the toughened laminate layer

Glass ionomer restoratives **from GC**

- a range to suit the majority of indications.



GC Fuji VIII GP - auto-cured resin - modified restorative

A superior auto-cured reinforced restorative when you need a cost-effective solution. Offering real aesthetic properties in the right translucency combined with improved physical properties and reliable bond strength, it's just the material that suits your budget for Class III, V and root surface restorations.

The benefits to you



Long-lasting bond due to strong chemical adhesion



Reaches 90% of its mechanical properties within just 10 minutes



Good translucency without light-curing



Fluoride release



Special formula with specific resins to provide a perfect match with Vita® shades, making it ideal for anterior restorations



Radiopacity



Excellent physical properties



Easy to use,
no isolation needed



Excellent biocompatibility

Main indications	Class I	Class II	Class III	Class IV	Class V	Liner	Base	Core build-up
GC Fuji VIII			✓		✓		✓	



GC Fuji II LC Improved light-cured restorative

Delightfully easy to use, Fuji II LC *Improved* is a light-curable, resin-modified glass ionomer which gives safe, effective and long-lasting results which simply look great. It's a perfect choice for anterior restorations like Class III and Class V or as a base.

The benefits to you



Beautiful aesthetic results from a wide range of shades



Strong, chemical adhesion unaffected by moisture: no etching or bonding agents needed



Light-curable for a controlled setting time



Excellent, long-lasting marginal seal



Improved mechanical properties such as wear resistance



High fluoride release



Biocompatible



Good radiopacity



Main indications	Class I	Class II	Class III	Class IV	Class V	Liner	Base	Core build-up
GC Fuji II LC Improved			✓		✓	✓	✓	

GC Fuji IX GP and GC Fuji IX GP FAST - packable glass ionomer

Fuji IX GP is one of the world's leading glass ionomer restoratives. A conventional, self-curing glass ionomer, it's easy to pack and contour in the cavity and works splendidly in posterior Class I, II, and V restorations. It's also ideal for core build-up or as a base.

With all the benefits of Fuji IX GP and for the same indications, Fuji IX GP FAST achieves restorations that last longer in only half the time – only 3 minutes from start of mixing to finish. If speed is of the essence, you'll want to use Fuji IX GP FAST.



The benefits to you



Packable and non-sticky, easy to place, easy to contour



Strong, self-curing chemical adhesion to cavity, unaffected by moisture: no need for etching or bonding agents



Preparation technique is gentle on teeth: no need for undercutting



Chemical setting allows single-step placement without layering



Ideal for immediate or postponed sandwich techniques



No shrinkage during setting, same thermal expansion as tooth structure



Excellent, long-lasting marginal seal



High wear resistance



High fluoride release



Biocompatible



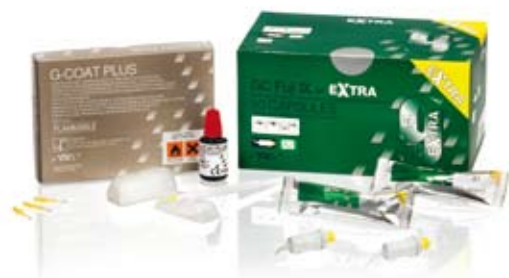Good radiopacity

Main indications	Class I	Class II	Class III	Class IV	Class V	Liner	Base	Core build-up
GC Fuji IX and GC Fuji IX FAST	✓	✓			✓		✓	✓

Last but not least – the next generation. The EQUIA Restorative System

What's so different about EQUIA? It helps you achieve aesthetics that remained impossible with conventional GICs. Finally, a glass ionomer technology paired with a coating that offers you the cost-efficient, time saving high-performance restorative system you've been crying out for. Based on the latest in glass ionomer technology this system offers unsurpassed wear resistance, compressive strength, durability and high fluoride release.

The EQUIA concept stands for Easy – Quick – Unique – Intelligent – Aesthetic. And it combines all the advantages of Fuji IX GP EXTRA with those of G-Coat PLUS to achieve the most effective posterior aesthetic restorations.



The benefits to you



Easy: bulk placement – no etching or bonding



Quick: from mixing to final, high gloss restoration in only 3'30"



Unique: improved wear resistance particularly suitable for replacing amalgams



Intelligent: improved fracture toughness and secondary maturation when it comes into contact with saliva over a period of time



Aesthetic: unique filler offers improved translucency for more natural shades to match the tooth structure



Six times higher fluoride release than standard glass ionomers



No need for rubber dam



Intrinsic adhesion to dentine and enamel



Single step placement



Good radiopacity



Excellent bio-compatibility

The EQUIA Restorative System: a truly economical, high-performance alternative for those posterior indications when you need to work quickly and produce beautiful aesthetics. Remember – how much a restoration costs greatly depends on how long your patient sits in the chair.

Main indications	Class I	Class II	Class III	Class IV	Class V	Liner	Base	Core build-up
GC Fuji IX GP EXTRA	✓	✓			✓		✓	✓

Glass ionomer restoratives from GC

- a range you'll turn to first, again and again.

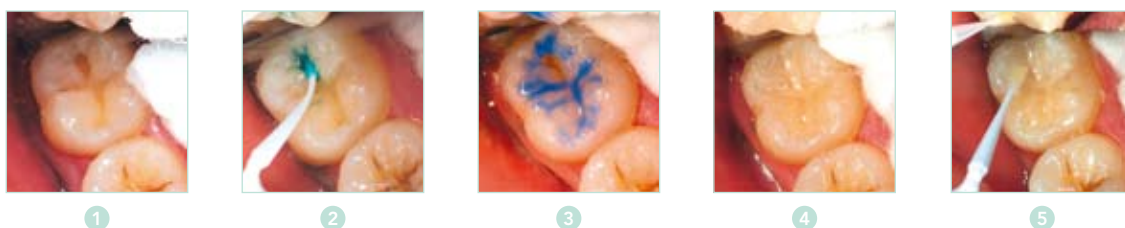A key aspect of today's Minimum Intervention Treatment Plan concept, created by GC, is carefully managing patient's mouth's and oral cavities over time. Here are some examples:

Restoring minimal carious lesions

The first cut of a tooth is actually the start of a destruction cycle. The outcome: a progressive loss of tooth structure since each restoration degrades and is subsequently replaced. When replacing dentine, use glass ionomer as the durable interface with dentine as part of your long term strategy to minimise the 'biological cost' to the tooth.

Ideally, replacement dentistry entails resurfacing a degraded restoration while maintaining the internal seal with no further loss of tooth structure. Repairing and maintaining existing restorations lies at the heart of a minimal intervention philosophy.

This is also possible with EQUIA.



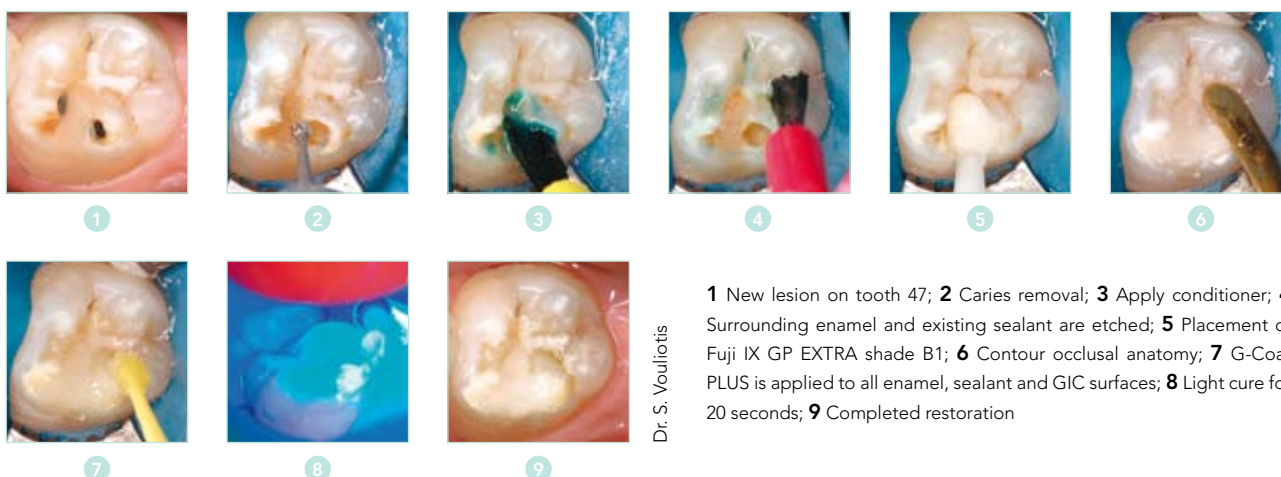
Dr G. Millich

1 Cavity preparation; **2** Conditioner is applied to dentine; **3** Un-cut enamel is acid etched; **4** Fuji IX GP Extra is placed; **5** G-Coat PLUS is applied to the glass ionomer and surrounding etched enamel

Continuing caries

Despite your best efforts with fissure sealants, new lesions can develop if your patient remains at high risk for caries. New lesions often develop around existing restorations – especially if hostile environmental factors remain unchanged.

The EQUIA system is ideal as a transitional restorative for patients with active decay and as part of a pulp protection strategy.

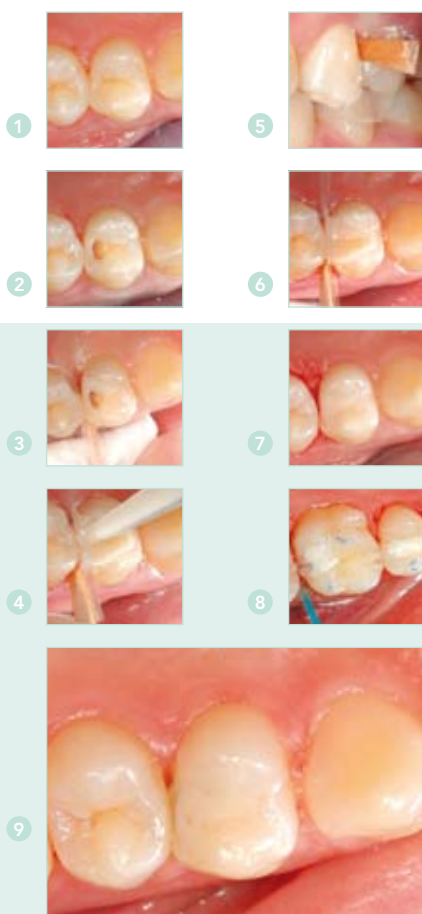

Dr. S. Vouliotis

1 New lesion on tooth 47; **2** Caries removal; **3** Apply conditioner; **4** Surrounding enamel and existing sealant are etched; **5** Placement of Fuji IX GP EXTRA shade B1; **6** Contour occlusal anatomy; **7** G-Coat PLUS is applied to all enamel, sealant and GIC surfaces; **8** Light cure for 20 seconds; **9** Completed restoration

Tunnel restorations

When you preserve the structural integrity of the peripheral rim, this actually strengthens the posterior tooth. With this in mind, use a tunnel preparation technique to remove proximal decay and access proximal lesions without compromising the rim.



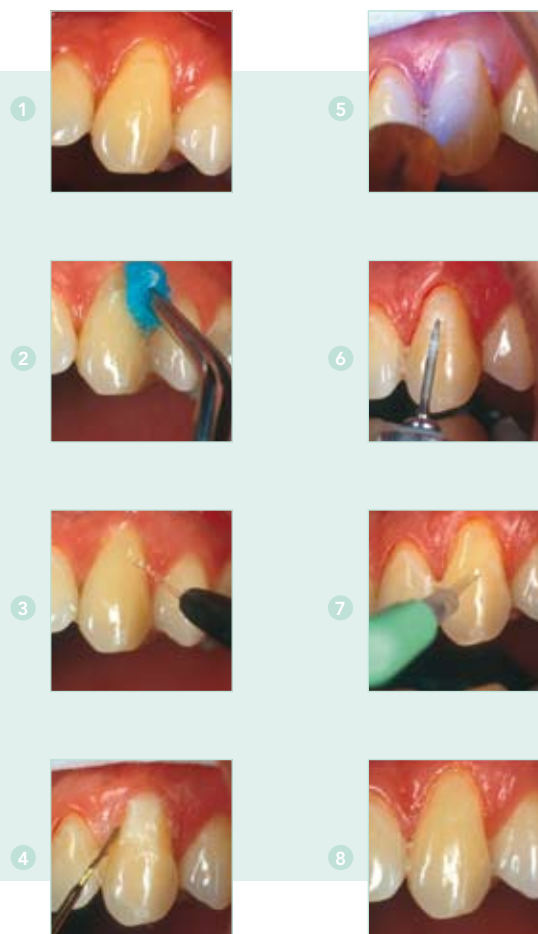Dr. G. Knight

1 Patient exhibits a distal lesion on an upper first premolar; **2** A "T" access cavity is created in the enamel and caries removed with #5 round bur; **3** A short Mylar strip is placed interproximally and wedged against the cavity preparation; **4** After conditioning, a glass ionomer is placed to slightly overfill the cavity; **5** The Mylar strip is pushed over the cement as the patient occludes; **6** The restoration is contoured and finished; **7** Completed restoration: the most conservative and aesthetic option for restoring an initial Class II cavity; **8** A layer of protective varnish may reduce proximal surface degradation of the glass ionomer restoration; **9** Tunnel restoration 14 months after placement.

Images first published in the ADANews Bulletin, No 358, 2007 and are reproduced with the permission of the Australian Dental Association Inc.

Cervical restorations

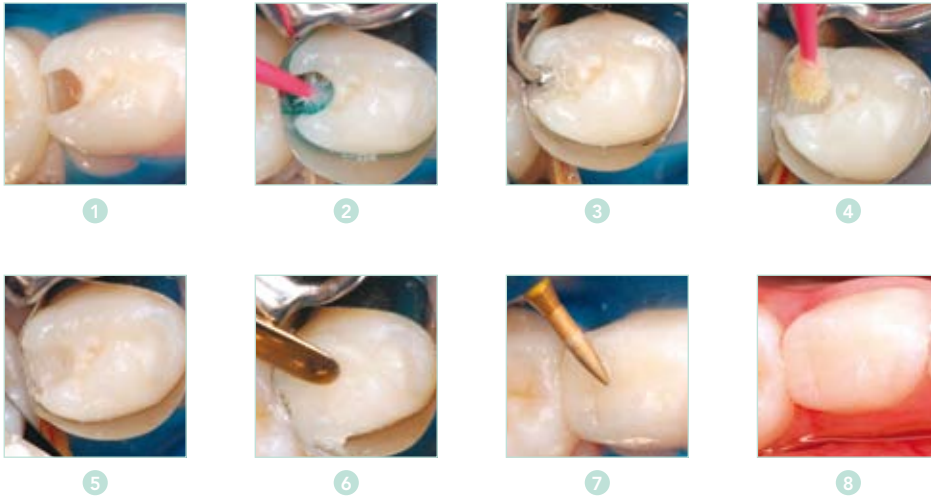
Achieve more aesthetic results in cervical cavities with the superior shade matching that resin-modified glass ionomers, such as Fuji II LC Improved, offer you. Reap the abundant benefits of the moisture tolerance of glass ionomers in these circumstances. And you'll achieve an even better marginal seal thanks to reliable chemical adhesion.



1 Cervical lesion; **2** After preparation of tooth, apply conditioner; **3** Washing and drying; **4** Form the contour and place a transparent matrix if required; **5** Light cure for 20 seconds; **6** Finish under water spray using superfine diamond bur, silicone point and polishing strips; **7** After polishing apply coating to protect the GIC during the first 24 hours; **8** Finished restoration

Pediatric proximal restorations

Use Fuji IX GP as a restorative material by itself or use it in conjunction with a composite in a laminate technique. The rapid working time and high fluoride release make it particularly suited to restorations for children.



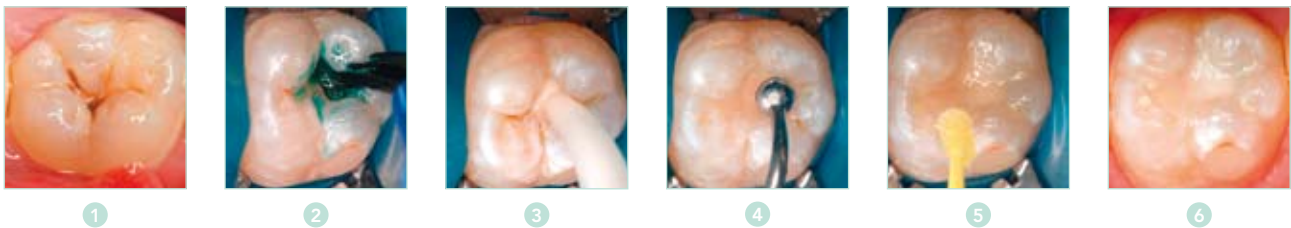
Dr. J. Lucas

1 Cavity preparation on Distal 84; **2** Apply conditioner for 10 second, wash and gently dry; **3** Place Fuji IX GP EXTRA shade B1 to form a base; **4** Apply G-Bond for 10 seconds to the cut enamel and GIC base; **5** G-Bond is vigorously air dried and light cured 10 seconds; **6** Shade A1 Gradia Direct posterior composite is applied and light cured; **7** Finish with fine diamonds; **8** Completed restoration

Minimal occlusal restorations in permanent teeth

Use glass ionomers to restore initial occlusal lesions with limited occlusal load, quickly and with minimal invasive techniques.

The EQUIA combination (Fuji IX GP EXTRA and G-Coat PLUS) offers durable adhesion and ultimate protection for the tooth, making your permanent restorations stronger and more resistant to wear.



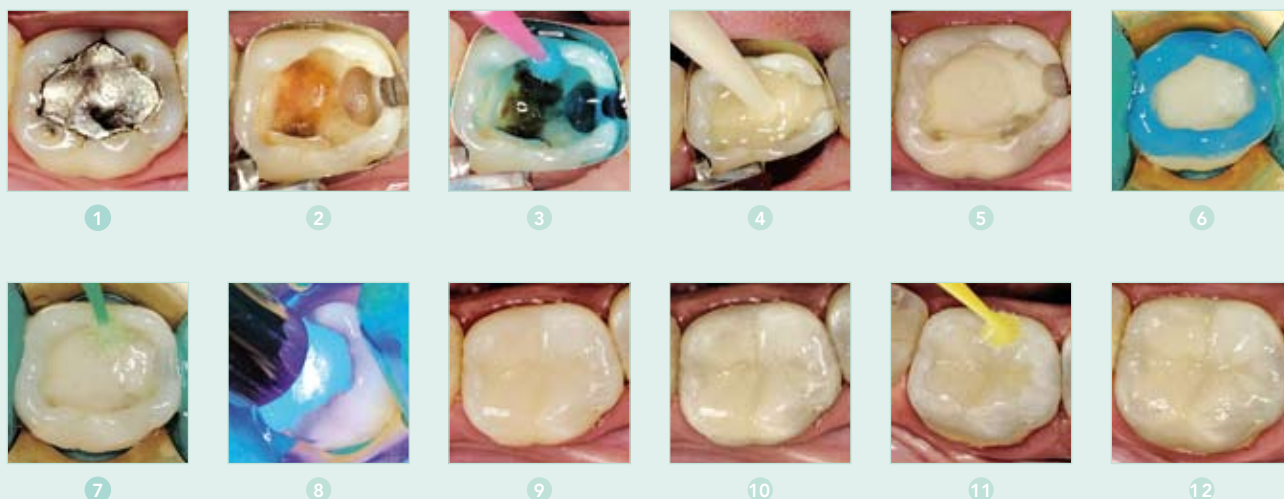Dr. J. Lucas

1 Occlusal caries; **2** Apply conditioner for 10 seconds; **3** Inject Fuji IX GP EXTRA; **4** Contour occlusal anatomy; **5** Apply G-Coat PLUS and light cure; **6** Finished restoration

Sandwich technique

When you're faced with higher occlusal load, or need to place restorations in highly acidic environments, use a packable glass ionomer and a composite restorative with a laminate technique. And whenever cavities are larger or under greater occlusal stress, you can place an external restorative material such as Gradia Direct Posterior over a base of Fuji IX GP or Fuji II LC. Although direct composite resin is often the external material used, you may also want to consider other types of indirect restoration as an option.

To perform the cut-back sandwich technique, overfill the cavity with glass ionomer, then cut back to form the shape and size of the cavity outline you want for the composite laminate. Proven to be very successful, you can enhance this combination by using G-Bond as the adhesive link between the glass ionomer and the composite.

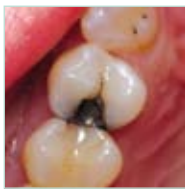

Dr. S. Lasocinski

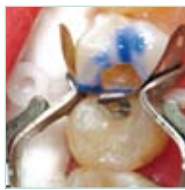1 Element before preparation; **2** Preparation ready; **3** Application of Cavity Conditioner for 10 seconds; **4** Application of Fuji IX GP FAST; **5** Fuji IX GP FAST base restoration ready; **6** Etching of enamel only; **7** Application of G-Bond; **8** Light-curing of bonding agent; **9** Composite placement incl. VLC curing; **10** Finished composite restoration; **11** Application of G-Coat PLUS; **12** Finished sandwich restoration

Replacing existing restorations

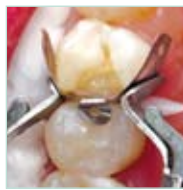When existing proximal restorations fail due to continuing caries activity, you might find it difficult to find a well-shaded restoration that offers a durable seal, protects the tooth and withstands an acidic oral environment – yet represents good value for your money and actually looks nice. In these situations, use a closed sandwich technique with Fuji IX GP. First seal and protect the tooth, then laminate all exposed external surfaces with composite resin (such as Gradia Direct Posterior).



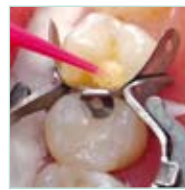1



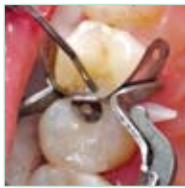2



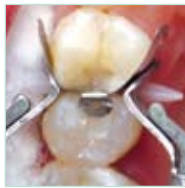3



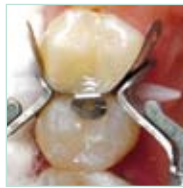4



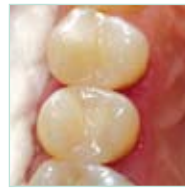5



6



7



8

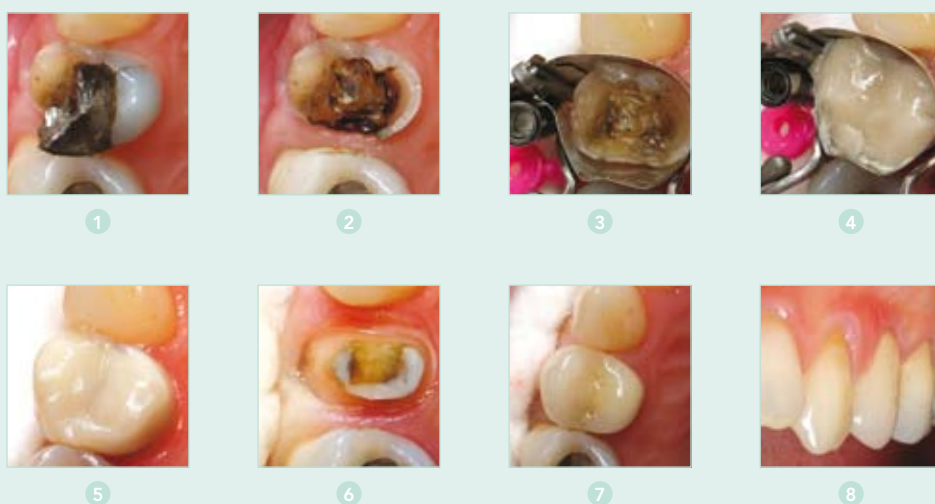Dr. G. Millicich

1 An amalgam restoration in tooth 24 has recurrent caries and requires replacement.; **2** Dentine is conditioned with 10% polyacrylic acid and enamel etched with 37% phosphoric acid gel.; **3** Fuji IX GP EXTRA is injected into the cavity to form a base.; **4** G-Bond is applied to the etched enamel and Fuji IX GP EXTRA base. Light-cure for 10 seconds.; **5** A flowable resin is placed on the gingival margin and polymerised.; **6** Gradia Direct Posterior (A2) is placed and sectioned into increments to reduce shrinkage stress.; **7** A final layer of Gradia Direct Posterior Natural Translucent is placed and light-cured.; **8** Completed restoration after finishing and polishing.



Transitional restorations and cores

Glass ionomers are an ideal transitional restorative material when you need to treat fractured cusps immediately in emergencies. Once you've performed the transitional restoration, your patient can schedule a later appointment for a prosthetic restoration. In treating fractures, be sure to create a first-rate dentine ferrule to cut down the glass ionomer restoration and use it to form part of the core for a crown.



Dr. G. Milich

1 Initial patient presentation; **2** Amalgam and fractured palatal cusp removed; **3** Matrix in place; **4** Placement of GC Fuji IX GP EXTRA; **5** Completed Fuji IX GP EXTRA transitional restoration; **6** Crown preparation four weeks later; **7** Fitted crown occlusal view; **8** Fitted crown facial view.

Selection Guide

TYPE OF RESTORATIVE	Resin-modified Glass Ionomer	Resin-modified Glass Ionomer	Packable Glass Ionomer	Packable Glass Ionomer
	GC Fuji VIII	GC Fuji II LC Improved	GC Fuji IX GP and GC Fuji IX GP FAST	GC Fuji IX GP EXTRA/ GC EQUIA
RESTORATIVE INDICATIONS				
Class I/II restorations, deciduous teeth			✓	✓
Class I/II semi-permanent restorations in permanent (pre)molars			✓	✓
Class III restorations	✓	✓	✓	
Class V, root surface caries, cervical erosions	✓	✓	✓	✓
Liner under amalgam or composite restorations		✓		
Base under amalgam, composite or porcelain inlays and onlays	✓	✓	✓	✓
Core build-up			✓	✓
FEATURES				
Conditioner	Yes	Yes	Yes	Yes
Radiopacity	Yes	Yes	Yes	Yes
High fluoride release	Yes	Yes	Yes	Yes
Aesthetic properties	Good	Excellent	Moderate	Excellent
Physical properties	Good	Good	Excellent	Excellent
Working time P/L	1'30"	3'45" P/L	2'00" Fuji IX GP P/L	1'15" Caps
Capsules	1'30"	3'15" Caps	2'00" Fuji IX GP Caps	
			1'15" Fuji IX GP FAST	
Setting time P/L	3'30"	20" light curing	4'15" Fuji IX GP P/L	2'00" Caps
Capsules	3'45"		4'30" Fuji IX GP Caps	
			3'00" Fuji IX GP FAST	
Available shades	A2, A3, A3.5, B2, B3, C4	A1, A2, A3, A3.5, A4, B2, B3, B4, C2, C4, D2	A1**, A2, A3, A3.5, B2, B3, C4	A1**, A2, A3, A3.5, B2, B3, C4
Delivery from	Capsules 50 capsules assorted or separate (min. mixed volume per capsule: 0.10mL) Powder-Liquid: 1-1pkg; 15g powder, 8ml liquid, accessories Refill: Bottle of 15g powder, Bottle of 8ml liquid	Capsules 50 capsules assorted or separate (min. mixed volume per capsule : 0.10mL) Powder-Liquid: 3-2 pkg; 3 x 15g powder (A2, A3, B3) 2 x 6.8ml liquid, accessoires Refill: Bottle of 15g powder, Bottle of 6.8ml liquid	GC Fuji IX GP and GC Fuji IX GP Fast Capsules 50 capsules (min mixed volume per capsule: 0.12ml) GC Fuji IX GP Powder-Liquid: 1-1 pkg; 15g powder, 6.4ml liquid, accessoires Refill: Bottle of 15g powder, Bottle of 6.4ml liquid	Capsules 50 capsules (min mixed volume per capsule: 0.12ml)

All times are measured from start of mix
Test conditions: temperature (23±1°C) Relative humidity (50±10%)
ISO 9917: 1991 (E) (Dental water based cements)

* only for GC Fuji II Capsules ** only for GC Fuji IX GP Fast

For literature see www.gceurope.com

GC EUROPE N.V.
Head Office
Interleuvenlaan 33
B – 3001 Leuven
Tel. +32.16.74.10.00
Fax. +32.16.40.48.32
info@gceurope.com
www.gceurope.com

GC UNITED KINGDOM Ltd.
12-15, Coopers Court
Newport Pagnell
UK – Bucks. MK16 8JS
Tel. +44.1908.218.999
Fax. +44.1908.218.900
info@uk.gceurope.com
www.uk.gceurope.com

